

**UNIVERSIDAD CATÓLICA
DE SANTIAGO DE GUAYAQUIL
ESCUELA DE GRADUADOS EN CIENCIAS DE LA SALUD
ESPECIALIZACIÓN EN CIRUGÍA PEDIÁTRICA**

TEMA:

A COMPARATIVE EVALUATION BETWEEN SANTULLI-TYPE ILEOSTOMY AND
ALTERNATIVE ILEOSTOMY TECHNIQUES IN NEONATES”

AUTORA:

Pólit Guerrero Verónica Alexandra

TRABAJO DE INVESTIGACIÓN PREVIO A LA OBTENCIÓN
DEL TÍTULO DE:
ESPECIALISTA EN CIRUGÍA PEDIÁTRICA

TUTOR:

Salinas Salinas Vicente Aníbal

Guayaquil, Ecuador

2024



UNIVERSIDAD CATÓLICA
DE SANTIAGO DE GUAYAQUIL

SISTEMA DE POSGRADO

ESCUELA DE GRADUADOS EN CIENCIAS DE LA SALUD

CERTIFICACIÓN

Certificamos que el presente trabajo de titulación, fue realizado en su totalidad por **Pólit Guerrero Verónica Alexandra**, como requerimiento para la obtención del título de **Especialista en Cirugía Pediátrica**

TUTOR (A)

f. _____
Salinas Salinas Vicente Aníbal

DIRECTOR DEL PROGRAMA

f. _____
Acosta Farina Daniel Benigno

Guayaquil, a los 29 días del mes de enero del año 2024



UNIVERSIDAD CATÓLICA
DE SANTIAGO DE GUAYAQUIL

SISTEMA DE POSGRADO

ESCUELA DE GRADUADOS EN CIENCIAS DE LA SALUD

DECLARACIÓN DE RESPONSABILIDAD

Yo, **Pólit Guerrero, Verónica Alexandra**

DECLARO QUE:

El Trabajo de Titulación, **A COMPARATIVE EVALUATION BETWEEN SANTULLI-TYPE ILEOSTOMY AND ALTERNATIVE ILEOSTOMY TECHNIQUES IN NEONATES** previo a la obtención del título de **Especialista en Cirugía Pediátrica**, ha sido desarrollado respetando derechos intelectuales de terceros conforme las citas que constan en el documento, cuyas fuentes se incorporan en las referencias o bibliografías. Consecuentemente este trabajo es de mi total autoría.

En virtud de esta declaración, me responsabilizo del contenido, veracidad y alcance del Trabajo de Titulación referido.

Guayaquil, a los 29 días del mes de enero del año 2024

EL AUTOR (A)

f. _____
Pólit Guerrero Verónica Alexandra



UNIVERSIDAD CATÓLICA
DE SANTIAGO DE GUAYAQUIL

SISTEMA DE POSGRADO

ESCUELA DE GRADUADOS EN CIENCIAS DE LA SALUD

AUTORIZACIÓN

Yo, Pólit Guerrero, Verónica Alexandra

Autorizo a la Universidad Católica de Santiago de Guayaquil a la **publicación** en la biblioteca de la institución del Trabajo de Titulación, **A COMPARATIVE EVALUATION BETWEEN SANTULLI-TYPE ILEOSTOMY AND ALTERNATIVE ILEOSTOMY TECHNIQUES IN NEONATES**, cuyo contenido, ideas y criterios son de mi exclusiva responsabilidad y total autoría.

Guayaquil, a los 29 días del mes de enero del año 2024

EL (LA) AUTOR(A):

f. _____
Pólit Guerrero, Verónica Alexandra



A comparative evaluation between Santulli-Type Ileostomy and Alternative Ileostomy Techniques in neonates

< 1%
Textos sospechosos

0% Similitudes
0% similitudes entre comillas (ignorado)
0% entre las fuentes mencionadas

2% Idioma no reconocido (ignorado)

Nombre del documento: MV-Vol5-N4-2023-Art14.pdf
ID del documento: 85b0a7dabbd00e7e385598af9eb10e39068c9a45
Tamaño del documento original: 1,12 MB
Autor: Verónica Pólit Guerrero

Depositante: Verónica Pólit Guerrero
Fecha de depósito: 29/1/2024
Tipo de carga: url_submission
fecha de fin de análisis: 29/1/2024

Número de palabras: 4744
Número de caracteres: 35.788

Ubicación de las similitudes en el documento:



Fuentes principales detectadas

Nº	Descripciones	Similitudes	Ubicaciones	Datos adicionales
1	doi.org A comparative evaluation between Santulli-Type Ileostomy and Alternativ... https://doi.org/10.47606/ACVEN/MV0221	5%		Palabras idénticas: 5% (227 palabras)
2	www.ncbi.nlm.nih.gov The safety and effectiveness of Santulli enterostomy in n... https://www.ncbi.nlm.nih.gov/pmc/articles/PMC9845765/ 2 fuentes similares	2%		Palabras idénticas: 2% (75 palabras)
3	doi.org :: APS :: Advances in Pediatric Surgery https://doi.org/10.13029/jkaps.2018.24.1.20 3 fuentes similares	< 1%		Palabras idénticas: < 1% (47 palabras)
4	pubmed.ncbi.nlm.nih.gov Timing of neonatal stoma closure: a survey of health p... https://pubmed.ncbi.nlm.nih.gov/34413091/ 1 fuente similar	< 1%		Palabras idénticas: < 1% (39 palabras)
5	www.ncbi.nlm.nih.gov Autologous Intestinal Reconstruction Surgery in Short Bo... https://www.ncbi.nlm.nih.gov/pmc/articles/PMC9023091/ 2 fuentes similares	< 1%		Palabras idénticas: < 1% (24 palabras)

Fuentes con similitudes fortuitas

Nº	Descripciones	Similitudes	Ubicaciones	Datos adicionales
1	www.ncbi.nlm.nih.gov Complex gastroschisis with apple peel jejunoileal atresia, ... https://www.ncbi.nlm.nih.gov/pmc/articles/PMC9046871/	< 1%		Palabras idénticas: < 1% (32 palabras)
2	www.ncbi.nlm.nih.gov https://www.ncbi.nlm.nih.gov/pmc/articles/PMC5224761/pdf/jns-6-4.pdf	< 1%		Palabras idénticas: < 1% (34 palabras)
3	pubmed.ncbi.nlm.nih.gov The safety and effectiveness of Santulli enterostomy i... https://pubmed.ncbi.nlm.nih.gov/36683787/	< 1%		Palabras idénticas: < 1% (26 palabras)
4	pubmed.ncbi.nlm.nih.gov Santulli enterostomy revisited: indications in adults - ... https://pubmed.ncbi.nlm.nih.gov/16927062/	< 1%		Palabras idénticas: < 1% (28 palabras)
5	pubmed.ncbi.nlm.nih.gov Radiologic Image-Guided Tube Stoma Insertion in Neo... https://pubmed.ncbi.nlm.nih.gov/31436514/	< 1%		Palabras idénticas: < 1% (22 palabras)

Fuente ignorada Estas fuentes han sido retiradas del cálculo del porcentaje de similitud por el propietario del documento.

Nº	Descripciones	Similitudes	Ubicaciones	Datos adicionales
1	www.frontiersin.org Frontiers The safety and effectiveness of Santulli enterost... https://www.frontiersin.org/articles/10.3389/fped.2022.1077346/full	2%		Palabras idénticas: 2% (100 palabras)

Fuentes mencionadas (sin similitudes detectadas) Estas fuentes han sido citadas en el documento sin encontrar similitudes.

1	https://orcid.org/0000-0002-2060-6590
2	https://orcid.org/0000-0002-9655-2824
3	https://orcid.org/0000-0002-0007-3168
4	https://orcid.org/0000-0001-8268-4271
5	https://orcid.org/0000-0002-3748-4585

A comparative evaluation between Santulli-Type Ileostomy and Alternative Ileostomy Techniques in neonates

Evaluación comparativa entre la ileostomía tipo Santulli y técnicas alternativas de ileostomía en neonates

<https://doi.org/10.47606/ACVEN/MV0221>

Verónica Polit-Guerrero 1, 2,3*

<https://orcid.org/0000-0002-2060-6590>

veronica.polit.g@gmail.com

Vicente Salinas-Salinas 2, 3

<https://orcid.org/0000-0002-0007-3168>

vicentico2712@hotmail.com

Jimmy Andrade-Montesdeoca^{1, 2, 3}

<https://orcid.org/0000-0002-3748-4585>

jimmy_andm@hotmail.com

Daniel Acosta-Farina 1, 2, 3

<https://orcid.org/0000-0002-9655-2824>

acofa111@yahoo.es

Lin Mei Chun 1, 2, 3

<https://orcid.org/0000-0001-8268-4271>

meilinch804@gmail.com

Rodrigo Argotti-Zumbana^{1, 2}

<https://orcid.org/0000-0002-1626-3839>

danielsan_0411@hotmail.com

Recibido: 18/05/2023

Aceptado: 25/08/2023

ABSTRACT

Introduction: Neonates often encounter various gastrointestinal malformations, necessitating surgical interventions. However, specific guidelines for choosing the ileostomy technique in these cases are lacking. The Santulli-type ileostomy has gained recognition for its benefits, including reduced complications and early restoration of intestinal transit. The aim of this study is to compare the outcomes of the Santulli-type ileostomy with alternative ileostomy techniques. **Materials and methods:** This is a case-control study. Statistical tests, such as chi-square (χ^2), relative risk, and confidence interval, were used for comparisons, with p-values indicating the significance of observed differences. Complications during ileostomy permanence, restoration surgery, and nutritional status were analyzed. **Results:** A total of 58 patients who had undergone ileostomies were included in the analysis (Santulli group: 27, Control group: 31). Santulli ileostomies demonstrated significantly lower prolapse rates ($p = 0.03$) and fewer readmissions due to dehydration ($p = 0.008$). Santulli ileostomies showed a trend towards more frequent restoration surgeries ($p = 0.2$) with shorter ileostomy duration. Caliber differences, stoma closure materials, and complications after restoration surgery favored Santulli ileostomies. **Conclusion:** Our findings emphasize the benefits of Santulli-type ileostomies in neonates, highlighting their efficacy in reducing complications, enabling early restoration surgery, and facilitating a quicker recovery.

Keywords: ileostomy, laparotomy, necrotizing enterocolitis, neonate, prolapse, Santulli-type

1. Pediatric Surgery Program, Catholic University of Santiago de Guayaquil, Guayaquil

2. Department of Pediatric Surgery, Dr. Roberto Gilbert Elizalde Children's Hospital. Guayaquil-Ecuador 3. Pacific Association of Pediatric Surgeons Member

* Corresponding author: veronica.polit.g@gmail.com

RESUMEN

Introducción: Los neonatos a menudo se enfrentan a diversas malformaciones gastrointestinales que requieren intervenciones quirúrgicas. Sin embargo, carecemos de pautas específicas para elegir la técnica de ileostomía en estos casos. La ileostomía tipo Santulli ha ganado reconocimiento por sus beneficios, que incluyen una reducción de complicaciones y una pronta restauración del tránsito intestinal. El objetivo de este estudio es comparar los resultados de la ileostomía tipo Santulli con técnicas alternativas de ileostomía. **Materiales y métodos:** Se trata de un estudio de casos y controles. Se utilizaron pruebas estadísticas, como el chi-cuadrado (χ^2), riesgo relativo e intervalo de confianza, para comparaciones, con valores de p indicando la significancia de las diferencias observadas. Se analizaron las complicaciones durante la permanencia de la ileostomía, la cirugía de restauración y el estado nutricional. **Resultados:** Se incluyeron en el análisis un total de 58 pacientes que se sometieron a ileostomías (grupo Santulli: 27, grupo de control: 31). Las ileostomías Santulli mostraron tasas significativamente más bajas de prolapso ($p = 0.03$) y menos readmisiones debido a la deshidratación ($p = 0.008$). Las ileostomías Santulli mostraron una tendencia hacia cirugías de restauración más frecuentes ($p = 0.2$) con una duración más corta de la ileostomía. Las diferencias de calibre, los materiales de cierre de la estoma y las complicaciones después de la cirugía de restauración favorecieron a las ileostomías Santulli. **Conclusión:** Nuestros hallazgos enfatizan los beneficios de las ileostomías tipo Santulli en neonatos, destacando su eficacia en la reducción de complicaciones, la posibilidad de realizar cirugías de restauración temprana y facilitar una recuperación más rápida.

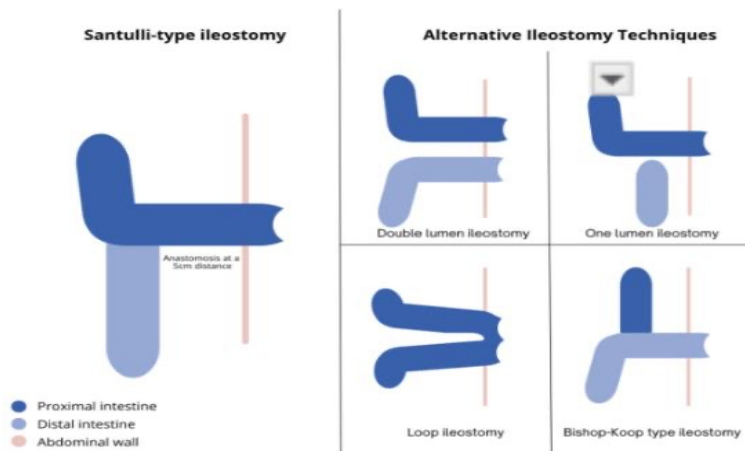
Palabras clave: ileostomía, laparotomía, enterocolitis necrotizante, neonato, prolapso, ileostomía tipo Santulli.

INTRODUCTION

Neonates frequently experience a diverse array of digestive disorders, stemming from either congenital factors or the underdeveloped state of their gastrointestinal tract. In specific cases, urgent surgical interventions become imperative to redirect intestinal transit and expedite recovery. The establishment of a stoma has been recognized as an effective therapeutic approach, significantly reducing both short- and long-term morbidity and mortality. Despite this recognition, specific guidelines to assist in the selection of the most appropriate type of ostomy tailored to individual patients and circumstances are currently lacking. The most commonly used ileostomies include double-lumen single-lumen, loop, and currently, the Santulli-type ileostomy (Figure 1).

Figure1.

Illustrated Types of Ileostomies



Santulli-type Ileostomy: Proximal intestine brought to the abdominal wall, anastomosis with distal intestine made 5cm away on the antimesenteric border.

Double lumen Ileostomy: Both proximal and distal intestinal segments brought to the abdominal wall, creating two separate stomas.


Single lumen Ileostomy: Proximal intestine brought to the abdominal wall; distal intestine closed inside the abdominal cavity.

Loop Ileostomy: intestine brought out through the abdominal wall; a cut made for intestinal content drainage without complete sectioning.

Bishop-Koop Ileostomy: distal intestine brought to the abdominal wall; end-to-side anastomosis performed with proximal intestine.

The Santulli-type ileostomy has emerged as a prominent approach, presenting substantial advantages (1). This surgical technique involves exposing the proximal intestine through the abdominal wall and performing an end-to-side anastomosis with the distal intestine, typically around 5cm away on the antimesenteric side (Figure 1).

The deliberate restriction of the stoma opening in the Santulli-type ileostomy proves instrumental in preventing potential mechanical complications, such as prolapse. Furthermore, the technique optimizes intestinal preservation by maintaining partial flow in the distal intestine, effectively decompressing the proximal intestine without rendering the distal segment entirely non-functional.




This preservation of caliber and absorptive surface area serves to mitigate long-term risks of malnutrition and reduce emergency visits due to dehydration. The primary objective of this study was to compare the outcomes associated with Santulli-type ileostomies against alternative ileostomy techniques in neonates, emphasizing the prevention of mechanical and clinical complications, achievement of early restoration of intestinal transit, and facilitation of less extensive surgical procedures.

While existing literature unequivocally presents evidence regarding the superiority of Santulli-type ileostomies in neonates, it is important to note that at our institution, the choice of technique ultimately hinges on the proficiency and expertise of the surgeon (2). This research seeks to enhance our understanding, aiding medical decision-making and ensuring the best possible outcomes for neonatal patients.

MATERIALS AND METHODS

The research was a retrospective and analytical employing a case-control methodology within an observational framework. Approval for the study was obtained from the Educational Division of the Dr. Roberto Gilbert Elizalde Children's Hospital in Guayaquil, Ecuador. The study was conducted at the Dr. Roberto Gilbert Elizalde Children's Hospital between 2018 and 2023. The study was elaborated following the STROBE guidelines (Strengthening the Reporting of Observational Studies in Epidemiology) (3).

To identify cases, a comprehensive review of medical records was conducted. Specific International Classification of Diseases, Tenth Revision (ICD-10) codes related to ileostomies (Z432 and Z932) were applied. The inclusion criteria focused on neonatal patients who had undergone ileostomies, including those born at full term within the first 28 days of life and premature neonates who had reached up to 40 corrected gestational weeks. Exclusion criteria were applied to patients who underwent ileostomy at an advanced age. The sampling method in this study distinguished between Santulli-type ileostomies and alternative types, based on a categorical and nominal variable. Two groups were compared: the case group, including patients with Santulli-type ileostomies, and the control group, consisting of individuals with various alternative ileostomy techniques (double lumen ileostomy, one lumen ileostomy, loop ileostomy, and Bishop-Koop type ileostomy) (Figure 1).




Both groups were compared in terms of their demographic and clinical characteristics including gestational age, gender, birth weight, birth length, and age at ileostomy creation, as well as the diagnoses that led to the formation of stomas in each group (note that some patients presented with multiple concurrent diagnoses). Complications during ileostomy maintenance can be broadly categorized into surgical/mechanical and clinical complications.

Surgical/mechanical issues are expressed categorically and include instances such as wound infections, wound dehiscence, adhesive bowel obstruction, compartment syndrome, and prolapse. On the clinical side, complications encompass readmissions due to dehydration, measured categorically, and excessive fecal discharge, quantitatively defined as volumes exceeding 20ml/kg/day, falling into the category of ratio data. To stimulate transit to the distal intestine before intestinal transit restoration surgery, two techniques were performed: intermittent stoma occlusions for patients with a Santulli-type ileostomy and fecal transpositions for those with alternative ileostomy techniques (patients with double lumen and loop ileostomy). Fecal transposition involves the collection of intestinal content obtained from the proximal segment, which is then prepared to be placed via a catheter into the afunctional distal segment of the intestine (Table 1).

Table 1
Distal transit stimulation techniques

Technique	Case (Santulli-type ileostomy)	Control (alternative ileostomy techniques) *
	<i>Intermittent stoma occlusions</i>	<i>Fecal transpositions</i>
Materials	<input type="checkbox"/> 10FR Foley catheter for neonates <1500gr, balloon with 2ml of fluid <input type="checkbox"/> 12FR Foley catheter for neonates >1500gr, balloon with 2.5ml of fluid	<input type="checkbox"/> Ostomy bag <input type="checkbox"/> 50ml of saline solution <input type="checkbox"/> Gauze <input type="checkbox"/> 12-14FR Foley catheter <input type="checkbox"/> 20ml syringe
Beginning	When the patient could tolerate 30ml of enteral feeding.	No defined
Procedure	Introducing the Foley catheter into the stoma opening, inflating the balloon, and ensuring it does not slip.	The ostomy bag content was measured, diluted with 50ml saline, filtered through gauze, and introduced into the distal stoma using a 12-14FR Foley catheter with a 20ml syringe.
Timing	<input type="checkbox"/> 4 hours closed Foley catheter and 2 hours open (if no vomiting or abdominal distension) <input type="checkbox"/> Progress to 20 hours closed and 4 hours open <input type="checkbox"/> Then maintain the catheter closed permanently	<input type="checkbox"/> Every 8 hours <input type="checkbox"/> Infusion rate of 3ml per minute

*Double lumen and loop ileostomy



The group of patients undergoing surgery to restore intestinal transit was analyzed to assess nutritional status using standard deviation data provided by the CDC/WHO for weight-for-age at the moment of surgery. Taking into account the time of ileostomy permanence and the age at final ileostomy closure surgery. Specific surgical approaches included extended laparotomy or limited stoma incision with stoma closure, adhesiolysis, intestinal anastomosis, and ileocecal valve resection. Caliber differences between the proximal and distal bowels were compared.

Fasting was protocolled following the elective suture material for stoma closure or intestinal anastomosis with 3 days for mechanical suture and 5 days for manual suture. Postoperative complications following intestinal restoring surgery were assessed and included the necessity for re-ileostomy. The statistical analysis was conducted using IBM® SPSS® Statistics version 25, comparing two distinct groups: the case group, which had the Santulli-type ileostomy, and the control group with alternative ileostomy techniques.

Categorical variables were expressed as frequencies and percentages, while quantitative variables with a normal distribution were presented as means and standard deviations. For quantitative variables with a non-normal distribution, medians and ranges were reported.

The comparison of categorical variables was performed using the Chi-square test. Descriptive statistics, Chi-square, and p-value analyses were employed to assess the significance and relationships between variables. A significance level of $p < 0.05$ was considered statistically significant.

RESULTS

A total of 127 patients were initially evaluated. After applying exclusion criteria, 58 patients were selected for the study and categorized into two groups: the Case group, comprising 27 patients with a Santulli-type ileostomy, and the Control group, which included 31 patients with alternative ileostomy techniques (Figure 2). The analysis revealed that there were no significant differences between the groups. The most common diagnoses in both groups were necrotizing enterocolitis, followed by intestinal atresia (Table 2).






Figure 2
Overview of the Total Study Population

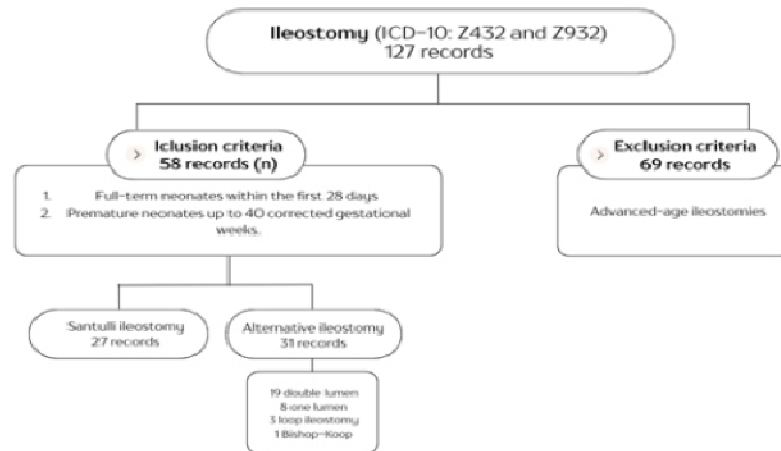


Table 2
General demographic data and diagnoses leading to Ileostomy creation

	Case (Santulli-type ileostomy) (n=27)	Control (alternative ileostomy techniques) (n=31)
<i>Demographic data</i>		
Gestational age (weeks)	Mean: 35,07 (min 29 – max 40)	Mean: 35,61 (min 27 – max 40)
Gender (n/%)	Female: 12 (44%) / Male: 15 (56%)	Female: 11 (35%) / Male: 20 (65%)
Birth weight (kg)	Mean: 2,20 (min 1 – max 3.8)	Mean: 2,24 (min 0,8 – max 4,1)
Birth length (cm)	Mean: 44,59 (min 33 – max 51)	Mean: 44,24 (min 35,5 – max 52)
Age at ileostomy creation (days)	Mean: 11,56 (min 1 – 41 max)	Mean: 9,29 (min 1 – max 39)
<i>Diagnosis</i>		
Necrotizing enterocolitis	9 (33,3%)	8 (25,8%)
Intestinal atresia (jejunum/ileum)	8 (29,6%)	6 (19,4%)
Intestinal volvulus	3 (11,1%)	-
Intestinal volvulus	2 (7,4%)	6 (19,4%)
Complicated Gastroschisis	2 (7,4%)	5 (16,1%)
Spontaneous intestinal perforation	2 (7,4%)	4 (12%)
Dehiscence (prior intestinal anastomosis)	2 (7,4%)	3 (9,7%)
Microcolon	2 (7,4%)	1 (3,2%)
Meconium pseudocyst	1 (3,7%)	1 (3,2%)
Complicated FIOP	1 (3,7%)	-
Complicated acute appendicitis	-	3 (9,7%)
Complicated Meckel's diverticulum	-	1 (3,2%)
Meconium ileus	-	1 (3,2%)
Colon atresia	-	-
Congenital colon stenosis	-	-
Mesenteric cyst	-	-

FIOP: Functional Intestinal Obstruction of Prematurity (4)

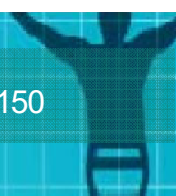


During the period of ileostomy maintenance, it became evident that patients with Santulli-type ileostomies experienced a significantly lower rate of complications compared to the group with alternative ileostomy techniques. Prolapse, which was the most common surgical/mechanical complication, was notably less frequent in the Santulli group, as evidenced by a chi-squared value of 4.32 and a statistically significant p-value of 0.03. From a clinical perspective, notable hospital readmissions due to dehydration were considerably less common in the Santulli group, with a chi-squared value of 6.86 and a p-value of 0.008, both of which were statistically significant. High fecal output was observed to a similar degree in both groups. Reinterventions necessitated by complications were also less frequent in the Santulli group. (Table 3).

Table 3
Complications during ileostomy permanence

	Case (Santulli-type ileostomy) (n=27)	Control (alternative ileostomy techniques) (n=31)	Relative Risk	Chi2	p value
<i>Surgical / Mechanical Complications</i>					
Reinterventions for complications	3 (11,1%)	13 (41,9%)	0,264	6,86	0,008
Obstructive abdomen	2 (7,4%)	6 (19,4%)	0,38	1,73	0,18
Prolapse	1 (3,7%)	7 (22,6%)	0,16	4	0,03
Wound dehiscence	1 (3,7%)	4 (12,9%)	0,28	1,55	0,21
Wound infection	-	2 (6,5%)	0	1,80	0,17
Abdominal wall hernia	-	2 (6,5%)	0	1,80	0,17
Urinary fistula	-	2 (6,5%)	0	1,80	0,17
Intestinal volvulus	-	2 (6,5%)	0	1,80	0,17
Compartment syndrome	-	-	-	-	-
<i>Clinical Complications</i>					
High fecal output	8 (29,6%)	11 (35,5%)	0,83	0,22	0,63
Readmissions due to dehydration	3 (11,1%)	20 (64,5%)	0,17	17,19	0.00003

In the context of preparing the distal intestine for intestinal transit restoration surgery, intermittent stoma occlusions were employed in 55.5% of patients in the Santulli group. In contrast, only 25.8% of patients with alternative ileostomy techniques underwent manual fecal transpositions. A total of 19 patients (70.3%) with Santulli-type ileostomies and 17 patients (54%) with alternative techniques underwent surgery to restore intestinal transit, demonstrating a chi-squared value of 1.47 and a p-value of 0.2.






While the chi-squared test did not indicate statistical significance, there was a notable trend towards a higher rate of surgery to restore intestinal transit in the Santulli group. For patients undergoing intestinal transit restoration surgery, the analysis included assessing their nutritional status at the time of the surgery.

It was observed that the Santulli ileostomy group exhibited standard deviations indicating a trend towards malnutrition and severe malnutrition. Significantly, the age at closure for the Santulli group corresponded to younger patients. Furthermore, the time interval from ileostomy creation to restoration surgery was notably shorter in the Santulli group, with the earliest restoration surgery occurring at just 3.1 weeks. (Table 4)

Table 4
Patients who underwent intestinal transit restoration surgery

	Case (Santulli-type ileostomy) (n=27)	Control (alternative ileostomy techniques) (n=31)	Relative Risk	Chi2	p value
<i>Surgery for restoration of intestinal transit</i>					
Yes	19 (70.3%)	17 (54%)	0,56 (0,32 – 1,32)	1,47	0,2
Age at ileostomy closure (days)	<i>n=19</i> Mean: 100 (min 25 – max 660)	<i>n=17</i> Mean: 286 (min 58 – max 1320)	-	36,00	0,33
Expected time to ileostomy closure (weeks)	Mean: 13,3 (min 3,1– max 93,9) Normal: 7 (36,8%) Malnutrition: 4 (21%)	Mean: 40,1 (min 7– max 188) Normal: 9 (52,9%) Malnutrition: 3 (17,6%)	-	36,00	0,37
Nutritional status at ileostomy closure	Severe malnutrition: 8 (42,1%)	Severe malnutrition: 5 (29,4%)	-	0,97	0,61
<i>Surgical approaches</i>					
	<i>n=19</i>	<i>n=17</i>			
	1 (5,2%)	15 (88,2%)	8,05 (2,12 – 29,7)	25,01	0,001
	18 (94,8%)	2 (11,7%)	0,06	25,01	0,001
	1 (5,2%)	11 (64,7%)	(0,009 - 0,4)	14,2	0,001
Extended laparotomy	1 (5,2%)	15 (88,2%)		21,7	0,001
Limited incision with stoma closure*	1 (5,2%)	2 (11,7%)		0,49	0,4
Adhesiolysis	2 (10,5%)	10 (58,8%)	2,68 (1,39 – 5,15)	9,41	0,002
Intestinal anastomosis			7,6 (2,05 – 28,2)		
Ileocecal valve resection			1,07 (0,87 – 1,31)		
Differences in caliber				2,17 (1,2 – 3,9)	




	Complications after surgery				
	n=19	n=17			
	1 (5,2%)	2 (11,7%)	1,07 (0,87	0,49	0,48
	1 (5,2%)	3 (17,6%)	- 1,31)	1,39	0,23
	1 (5,2%)	1 (5,8%)	1,15 (0,90	0,007	0,93
Sepsis	2 (10,5%)	1 (5,8%)	- 1,4)	0,25	0,6
			1,0 (0,85 -		
Obstructive abdomen	1 (5,2%)	-	1,1)	0,92	0,337
Wound dehiscence	2 (10,5%)	3 (17,6%)	0,95 (0,78	0,38	0,53
Enterocutaneous fistula			- 1,15)		
Incisional hernia					
Re-ileostomy			0,49 (0,85		
			- 1,05)		
			1,08 (0,83		
			- 1,42)		

* Control group: patients with loop ileostomy

In terms of surgical approaches for restoring intestinal transit, it was observed that the Santulli group predominantly favored limited incisions with stoma closure, while extended laparotomies, adhesiolysis, intestinal resection, intestinal anastomosis, and caliber differences were significantly associated with the control group, indicating a protective effect for Santulli ileostomy. Mechanical suture was the preferred elective material for 17 (89.4%) patients with Santulli ileostomy, resulting in a shorter fasting period per our protocol, in contrast to 5 (29.4%) patients in the control group. Furthermore, less common complications after intestinal restoration surgery included obstructive abdomen, with a lower frequency in the Santulli group. However, a slight tendency toward enterocutaneous fistula and incisional hernia was observed after limited incision closure in the Santulli group. Re-ileostomy requirements were also less frequent in the Santulli group (Table 4)

DISCUSSION

Neonates encounter a diverse range of digestive pathologies that often necessitate surgical interventions. These conditions stem from congenital/acquired anomalies and challenges resulting from gastrointestinal and immunological immaturity, manifesting in both full-term and preterm infants (1, 2, 5). Surgical procedures, including ileostomy creation, are typically urgent, aiming primarily at preserving life and correcting pathologies. It's noteworthy that these intestinal diversions are intended to be temporary, aiming to restore digestive functionality after the acute phase (5). Our referral center deals with diverse neonatal cases requiring ileostomies.



This study included all neonates with ileostomies, regardless of gestational age or birth weight. Demographic profiles exhibited similarities, with no specific criteria dictating the choice of ileostomy creation technique, aside from surgeon preference. Intestinal atresia was the most prevalent congenital pathology, while necrotizing enterocolitis held a predominant position in the acquired spectrum, consistent with Yue M et al (1). At present, the literature favors Santulli-type ileostomies, allowing for partial diversion of intestinal content. This approach preserves distal segment functionality and morphology, facilitating fluid and nutrient absorption, maintaining intestinal barrier integrity, and simplifying future surgical interventions for restoring intestinal transit (1, 2). Our current indications for choosing a Santulli-type ileostomy are outlined in Table 5.


Table 5

Indications to perform a Santulli-type ileostomy

Indications	Necrotizing enterocolitis
	Meconium pseudocyst
	FIOP with failed clinical management
	Microcolon
	Intestinal atresia with a 5:1 caliber disproportion and no possibility of intestinal resection
	Acute appendicitis with cecal perforation.
	Gastroschisis with no clinical improvement.
	Anastomotic leaks.
	Intestinal perforation.

After ileostomy creation, complications are a recognized phenomenon, involving cutaneous issues, surgical technique-related challenges, and clinical complications such as fecal output concerns, dehydration risk, and compromised intestinal function (6, 7, 8, 9). Cutaneous complications were not addressed in our study due to insufficient descriptive records, but they remain influential in-patient recovery. A Canadian study (4) suggests a potential link between primary incision proximity and ostomy site, although conclusive data is lacking.

Prolapse was the most prevalent surgical complication, especially in alternative techniques, requiring additional emergency visits. Santulli's ileostomy, with a 5cm anastomosis providing extra fixation, demonstrated protective properties against such events. Elevated fecal output, a common clinical complication in both groups, was significantly reduced in Santulli-type ileostomy, lowering the need for frequent hospital admissions due to dehydration (1, 9, 10).



During ileostomy management, various techniques were employed to stimulate distal segment function and morphology in preparation for intestinal transit restoration surgery. In the Santulli-type ileostomy group, interval stoma occlusions were performed to encourage rectal defecation (1).

Timing varied based on individual patient tolerance for abdominal discomfort, pain, or vomiting. For patients with alternative techniques, fecal transpositions were conducted. Family members were trained in these procedures before hospital discharge, with lower adherence observed in fecal transposition during outpatient visits. Coletta et al. (9) introduced tube-stomas as an alternative technique, utilizing proximal and distal catheters to achieve the same purpose as fecal transposition. This method controls the retrieval and transport of intestinal contents without direct manipulation of the ostomy bag or intestine, offering a potential developmental alternative (11).

For intestinal restoration surgery, Santulli-type ileostomy patients exhibited higher accessibility, considering age and nutritional status at surgery. Santulli-type ileostomy allowed for shorter durations, with no significant nutritional differences observed. No standardized ostomy closure protocol exists, and early or late closures may pose complications (12, 13, 14). A UK study suggested a 6-week closure timeframe, regardless of patient weight (13). Our closure decisions were based on surgeon evaluation and patient conditions.

Early closures were considered for the Santulli group if stoma occlusions were successful, with good tolerance for enteral feeding and rectal depositions, while a subgroup with high fecal output and dehydration delayed hospital discharge. Early closures occurred at 3.1 weeks after ileostomy creation in the Santulli group. Late closures were more common with alternative techniques, influenced by the COVID-19 pandemic which limited scheduled surgeries, and by socioeconomic challenges associated with our healthcare system as a private referral center (13).

Surgical procedures to restore intestinal transit are tailored to the type of ileostomy. We observed expedited recovery in these surgeries, especially in patients undergoing the Santulli technique. This method involved a streamlined procedure with smaller incisions around the ileostomy, reducing manipulation of intestinal loops and emphasizing the release of the abocated segment from the fascia for subsequent closure (1, 15, 16, 17).



In contrast, alternative ileostomy techniques required re-laparotomies with larger incisions, necessitating adhesiolysis and the potential for intestinal resections, which often involved the ileocecal valve—an essential component for intestinal absorption. Consequently, varied caliber segments and distal intestines were inconsistently prepared, influencing suture material preferences.

As previously mentioned, our fasting protocol was adjusted based on the elective surgical material used, enabling the Santulli group to start enteral feeding earlier. Both groups experienced complications (Figure 3), with obstructive abdomen being more frequent in the alternative technique group due to more extensive intestinal manipulation. In the Santulli group, enterocutaneous fistula and incisional hernia appeared in our initial cases, prompting a procedure adjustment that now emphasizes the complete liberation of the stoma from the fascia before closure with a mechanical suture, thereby reducing the risk of complications related to the abdominal wall, consistent with Yue et al.'s study (1). A percentage of patients required a new ileostomy due to the complexity of their clinical conditions

CONCLUSION


In summary, our study explored the significant advantages of Santulli-type ileostomies during the maintenance period. These benefits encompass the prevention of prolapses and a substantial reduction in hospital readmissions due to dehydration. Furthermore, the Santulli technique facilitates earlier intestinal transit restoration surgeries that are less complex and involve minimal intestinal manipulation, enabling a quicker return to enteral feeding and faster recovery.

While our study is limited as a single-center retrospective analysis, it offers valuable insights into the effectiveness of Santulli-type ileostomies in neonatal surgery. Recognizing constraints such as variations in care teams, absence of standardized protocols, and biases stemming from our private referral center status, the research underscores the significance of early interventions and the potential advantages associated with this specific ileostomy technique.

Despite challenges posed by the COVID-19 pandemic, our findings support endorsing the Santulli technique as the preferred option for neonatal ileostomies.

REFERENCES

1. Yue M, Yang H, Cui M, yuan Y, Zhang N, Zhang X, et al. The safety and effectiveness of santulli enterostomy in neonatal intestinal conditions. *Frontiers in Pediatrics*. 2023;10. doi:10.3389/fped.2022.1077346
2. Askarpour S, Ayatipour A, Peyvasteh M, Jahaherizadeh H. A comparative study between Santulli ILEOSTOMY and loop ileostomy in neonates with meconium ileus. *ABCD Arquivos Brasileiros de Cirurgia Digestiva (São Paulo)*. 2020;33(3):e1538. doi:10.1590/0102-672020200003e1538
3. STROBE Initiative. STROBE Statement—Checklist of items that should be included in reports of observational studies. STROBE; 2007. Available from: <https://www.strobestatement.org/index.php?id=strobe-home>. Accessed October 10, 2023.
4. Acosta Farina D, Polit-Guerrero V, Aguayo-Vistin J, Cedeño-Moreira C, Salinas-Salinas V, Acosta-Bowen D, et al. Functional intestinal obstruction of prematurity (FIOP): Short term management results: A case series. *Journal of Neonatal Surgery*. 2022; 11:13. doi:10.47338/jns. v11.1048
5. Harrell-Bean HA, Klell CA. Neonatal ostomies. *JOGN Nurs*. 1983;12(3 Suppl):69s-73s. doi:10.1111/j.1552-6909.1983.tb01103.x
6. Lockhat A, Kernaleguen G, Dicken BJ, van Manen M. Factors associated with neonatal ostomy complications. *Journal of Pediatric Surgery*. 2016;51(7):1135–7. doi: 10.1016/j.jpedsurg.2015.09.026
7. Aguayo P, Fraser JD, Sharp S, St Peter SD, Ostlie DJ. Stomal complications in the newborn with necrotizing enterocolitis. *J Surg Res*. 2009;157(2):275-278. doi: 10.1016/j.jss.2009.06.005
8. Kargl S, Wagner O, Pumberger W. Ileostomy Complications in Infants less than 1500 grams - Frequent but Manageable. *J Neonatal Surg*. 2017 Jan 1;6(1):4. doi: 10.21699/jns. v6i1.451. PMID: 28083490; PMCID: PMC5224761.
9. Coletta R, Zulli A, O'Shea K, Mussi E, Bianchi A, Morabito A. Minimizing Enterostomy Complication in Neonates, Lessons Learnt from Three European Tertiary Centres. *Children (Basel)*. 2022;9(2):162. Published 2022 Jan 27. doi:10.3390/children9020162
10. Brunette G. Novel Pouching Techniques for the Neonate with Fecal Ostomies. *J Wound Ostomy Continence Nurs*. 2017;44(6):589-594. doi:10.1097/WON.0000000000000384
11. Murphy F, Khalil BA, Gozzini S, King B, Bianchi A, Morabito A. Controlled tissue expansion in the initial management of the short bowel state [published correction appears in *World J Surg*. 2012 Feb;36(2):490]. *World J Surg*. 2011;35(5):1142-1145. doi:10.1007/s00268-011-0991-0
12. Zani A, Lauriti G, Li Q, Pierro A. The Timing of Stoma Closure in Infants with Necrotizing Enterocolitis: A Systematic Review and Meta-Analysis. *Eur J Pediatr Surg*. 2017;27(1):7-11. doi:10.1055/s-0036-1587333
13. Ducey J, Kennedy AM, Linsell L, Woolfall K, Hall NJ, Gale C, et al. Timing of neonatal stoma closure: A survey of health professional perspectives and current practice. *Archives of Disease in Childhood - Fetal and Neonatal Edition*. 2021;107(4):448–50. doi:10.1136/archdischild-2021-322040
14. Yang HB, Han JW, Youn JK, Oh C, Kim HY, Jung SE. The Optimal Timing of Enterostomy Closure in Extremely Low Birth Weight Patients for Acute



- Abdomen. *Sci Rep.* 2018;8(1):15681. Published 2018 Oct 24. doi:10.1038/s41598-018-33351-9
15. Lin Z, Liu M, Yan L, Wu L, Bai J, Wu D, et al. Outcome of santulli enterostomy in patients with immaturity of ganglia: Single institutional experience from a case series. *BMC Surgery.* 2022;22(1). doi:10.1186/s12893-022-01849-9
 16. Vinit N, Rousseau V, Broch A, Khen-Dunlop N, Hachem T, Goulet O, et al. Santulli procedure revisited in congenital intestinal malformations and postnatal intestinal injuries: Preliminary report of experience. *Children.* 2022;9(1):84. doi:10.3390/children9010084
 17. Castillo-Clavijo JL, Gálvez-Salazar PF, Ángel-Correa M, Montañez-Azcárate V, Palta-Urbe DA, Figueroa-Gutiérrez LM. Complex gastroschisis with apple peel jejunoileal atresia, primary closure, and Santulli procedure as a surgical alternative. Case report. *Int J Surg Case Rep.* 2022; 94:107095. doi: 10.1016/j.ijscr.2022.107095



DECLARACIÓN Y AUTORIZACIÓN

Yo, **Pólit Guerrero, Verónica Alexandra**, con C.C: # 1716432669 autor/a del trabajo de titulación: **A COMPARATIVE EVALUATION BETWEEN SANTULLI-TYPE ILEOSTOMY AND ALTERNATIVE ILEOSTOMY TECHNIQUES IN NEONATES** previo a la obtención del título de **Cirugía Pediátrica** en la Universidad Católica de Santiago de Guayaquil.

1.- Declaro tener pleno conocimiento de la obligación que tienen las instituciones de educación superior, de conformidad con el Artículo 144 de la Ley Orgánica de Educación Superior, de entregar a la SENESCYT en formato digital una copia del referido trabajo de titulación para que sea integrado al Sistema Nacional de Información de la Educación Superior del Ecuador para su difusión pública respetando los derechos de autor.

2.- Autorizo a la SENESCYT a tener una copia del referido trabajo de titulación, con el propósito de generar un repositorio que democratice la información, respetando las políticas de propiedad intelectual vigentes.

Guayaquil, **29 de enero de 2024**

f. _____

Nombre: Pólit Guerrero Verónica Alexandra

C.C: 1716432669



REPOSITORIO NACIONAL EN CIENCIA Y TECNOLOGÍA

FICHA DE REGISTRO DE TESIS/TRABAJO DE GRADUACIÓN

TÍTULO Y SUBTÍTULO:	A COMPARATIVE EVALUATION BETWEEN SANTULLI-TYPE ILEOSTOMY AND ALTERNATIVE ILEOSTOMY TECHNIQUES IN NEONATES		
AUTOR(ES) (apellidos/nombres):	Verónica Alexandra Pólit Guerrero		
REVISOR(ES)/TUTOR(ES) (apellidos/nombres):	Vicente Aníbal Salinas Salinas		
INSTITUCIÓN:	Universidad Católica de Santiago de Guayaquil		
UNIDAD/FACULTAD:	Escuela de Graduados en Ciencias de la Salud		
MAESTRÍA/ESPECIALIDAD:	Especialización en Cirugía Pediátrica		
GRADO OBTENIDO:	Cirujano Pediátrico		
FECHA DE PUBLICACIÓN:	9 de enero del 2024	No. DE PÁGINAS:	15
ÁREAS TEMÁTICAS:	Cirugía Neonatal, Neonatología, Cirugía Pediátrica		
PALABRAS CLAVES/KEYWORDS:	ileostomy, laparotomy, necrotizing enterocolitis, neonate, prolapse, Santulli-type		
RESUMEN/ABSTRACT (150-250 palabras):	<p>Background: Neonates often encounter various gastrointestinal malformations, necessitating surgical interventions. However, specific guidelines for choosing the ileostomy technique in these cases are lacking. The Santulli-type ileostomy has gained recognition for its benefits, including reduced complications and early restoration of intestinal transit. The aim of this study is to compare the outcomes of the Santulli-type ileostomy with alternative ileostomy techniques. Methods: This is a case-control study. Statistical tests, such as chi-square (χ^2), relative risk, and confidence interval, were used for comparisons, with p-values indicating the significance of observed differences. Complications during ileostomy permanence, restoration surgery, and nutritional status were analyzed. Results: A total of 58 patients who had undergone ileostomies were included in the analysis (Santulli group: 27, Control group: 31). Santulli ileostomies demonstrated significantly lower prolapse rates ($p = 0.03$) and fewer readmissions due to dehydration ($p = 0.008$). Santulli ileostomies showed a trend towards more frequent restoration surgeries ($p = 0.2$) with shorter ileostomy duration. Caliber differences, stoma closure materials, and complications after restoration surgery favored Santulli ileostomies. Conclusion: Our findings emphasize the benefits of Santulli-type ileostomies in neonates, highlighting their efficacy in reducing complications, enabling early restoration surgery, and facilitating a quicker recovery</p>		
ADJUNTO PDF:	<input checked="" type="checkbox"/> SI	<input type="checkbox"/> NO	
CONTACTO CON AUTOR/ES:	Teléfono: +593-987253129	E-mail: veronica.polit@cu.ucsg.edu.ec veronica.polit.g@gmail.com	
CONTACTO CON LA INSTITUCIÓN:	Nombre: Dr. Daniel Acosta Farina		
	Teléfono: +593 998638292		
	E-mail: daniel.acosta02@cu.ucsg.edu.ec acofa123@gmail.com acofa111@yahoo.es		
SECCIÓN PARA USO DE BIBLIOTECA			
Nº. DE REGISTRO (en base a datos):			
Nº. DE CLASIFICACIÓN:			
DIRECCIÓN URL (tesis en la web):			